PATIENT CARE THEORY 2

UNIT 5, PART 6: Complications in Labour & Delivery

Marilyn Niffin, BSc., ACP
Professor Georgian College
Patient Care Theory 2
Winter 2020, 2021, 2023

Topics

- Denied or hidden pregnancy
- Premature Ruptured Membranes
- Meconium Staining
- Breech Presentation
- Prolapsed Cord
- Limb Presentation
- Multiple Births
- Cephalopelvic Disproportion
- Precipitous Delivery
- Shoulder Dystocia
- Postpartum Hemorrhage
- Uterine Rupture
- Uterine Inversion
- Pulmonary Embolism; Amniotic Fluid Embolism

Denied or hidden Pregnancies

- Patient who unconsciously denies the existence of the pregnancy
  - Associated with psychological disorders
- Patient who is aware of, but conceals the pregnancy from family, partner, friends etc.
- Risks
  - Little to no prenatal care
  - Small for gestational age
  - Neonatal death
- May need to rely on physical assessments to determine ~ gestational age

Denied or Hidden Pregnancies

- If in labour, may be associated with mental health concerns
  - Depersonalization – patient reports unusually low level of pain
  - Dissociation
  - La Belle Indifference – bland, indifferent response to pregnancy and delivery
  - Dissociative Psychosis – labour pains described as “flu” or birth as a “bowel movement”.
    - Amnesia may follow the dissociative psychotic state

Association of Ontario Midwives, 2017; PESP

Premature Ruptured Membranes

- Occurs before the onset of contractions in about 10% of deliveries
- Can occur as a gush of fluid, but usually is only a trickle
- more fluid noticed when lying down rather than standing because the baby's head blocks cervix pt upright
- Amniotic fluid should be clear and slightly yellow or amber in color
- It should have a faint sweet smell, which can help differentiate it from urine
- contractions usually start within 12 hours of the membranes rupturing
- After 24 hours the risk of infection increases

Meconium Staining

- Fetus ingests amniotic fluid and excretes it every day through the kidneys
- Meconium is the first stool
- If the fetus is distresses, it may pass feces into the amniotic fluid.
  - greenish-black color and very sticky, tarry in its texture
- May be aspirated by the fetus
  - Can cause severe respiratory distress

Meconium Staining - Management

- If meconium is present ***and*** obstructing the A/W
  - Suction the hypopharynx using a bulb or other suction device
  - as much and as quickly as possible prior to stimulating the baby
  - Follow with PPV

- NRP with meconium aspiration and digital intubation

Breech Presentation

- The buttocks or both feet present first.

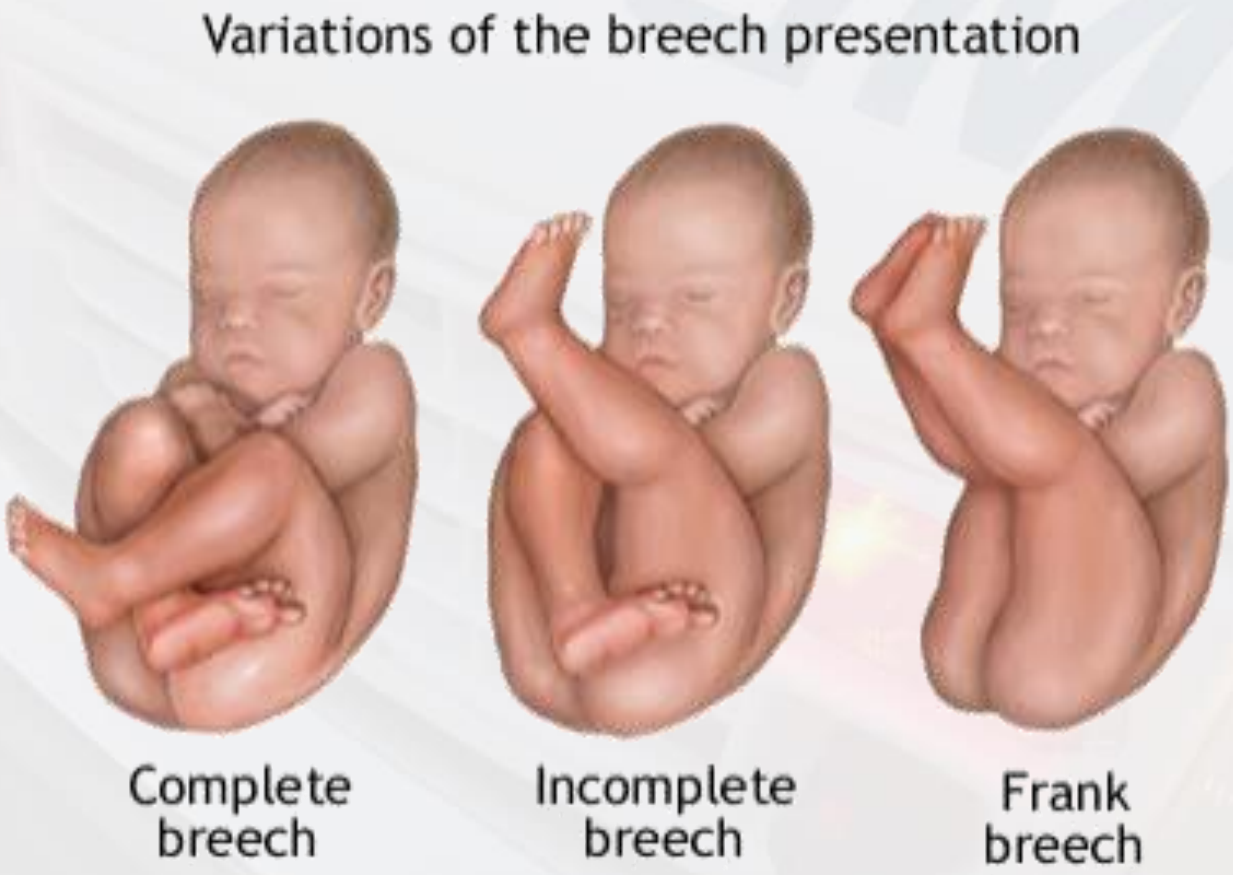

Breech Birth

- More common
  - premature deliveries
  - Uterine abnormalities
  - Multiple gestations
  - Low lying placenta
  - Congenital abnormalities
- However – majority of patients with a breech presentation have no known risk factors

Consult

- In any complex delivery, contact the BHP for a consultation

Management

- Communicate with the patient and family, and other paramedics
- Position the patient to allow gravity (to help birth the baby) use the edge of the bed and place pt. feet on a chair
- Minimize handling of the breech newborn (this is to avoid stimulating the newborn to breathe)
  - Avoid intervention until at least the umbilicus is visible if possible (note the time: **Delivery should occur within 4 minutes at this time****)

Breech Presentation

1. Hand off approach and allow the buttocks to deliver
2. When you see the pelvis, assess the need to assist with delivery of the legs
3. If necessary, grasp it & rotate the baby so that the back is facing anterior (if not already)
4. Place finger behind the knee of one leg, flex the knee and deliver the leg
5. Do the same for the other leg

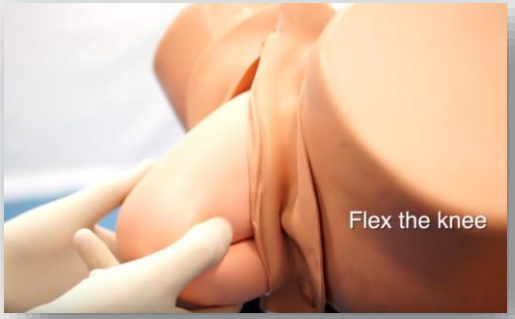

Breech Presentation

6. Continue with hands off
7. Allow baby to descend with gravity
8. Assess the need to assist with arm delivery
9. Rotate baby to side position to release one arm – do the same with other arm
10. Allow delivery to progress and gravity to birth the baby
    - If delivery does not occur and the hairline is visible, perform the Mauriceau-Smellie- Veit maneouver

Breech Presentation

Form a “V” and push the vaginal wall away from infant’s face

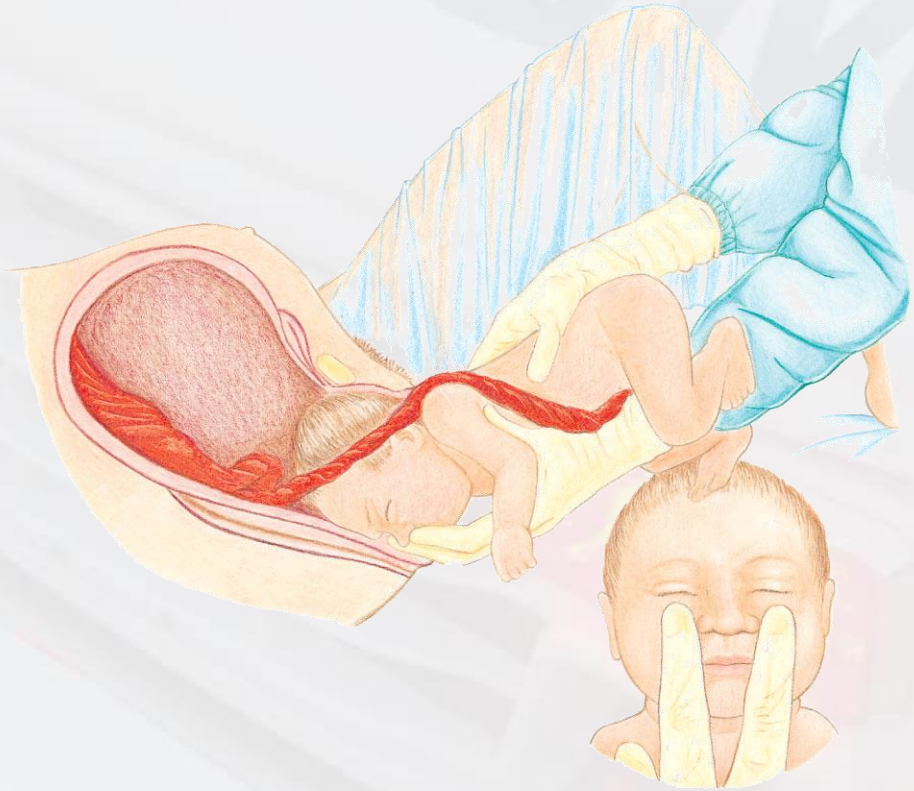

FIGURE 40-20 Placement of the fingers to maintain the airway in a breech birth.

Mauriceau-Smellie-Veit Manoeuvre

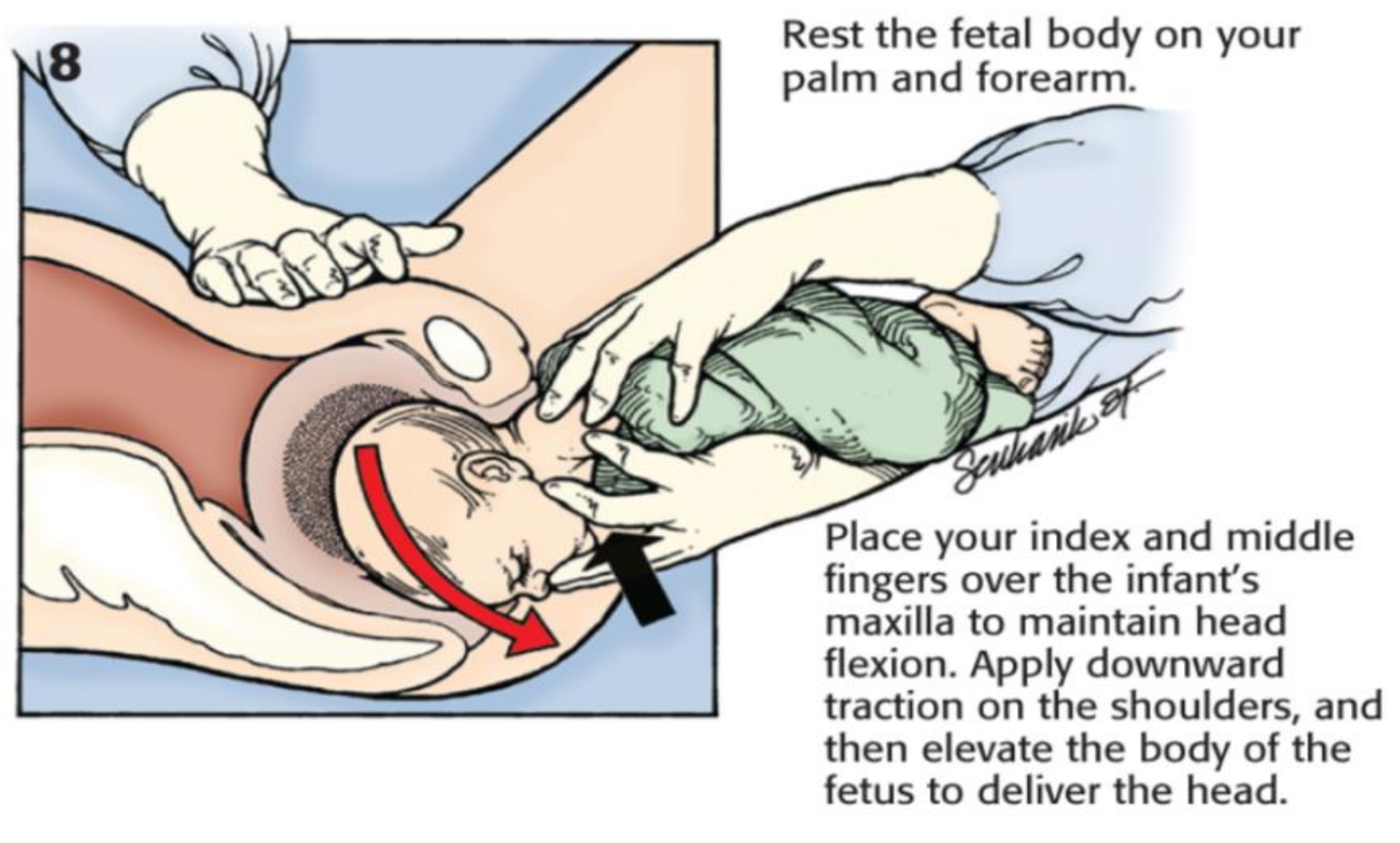

Shoulder Dystocia

Shoulder Dystocia

- Dystocia means difficult labour
- Infant's shoulders are larger than its head.
- **Turtle sign**
  - Head comes out, then retracts
  - Head may stay out but *shoulder is stuck against the symphysis pubis*

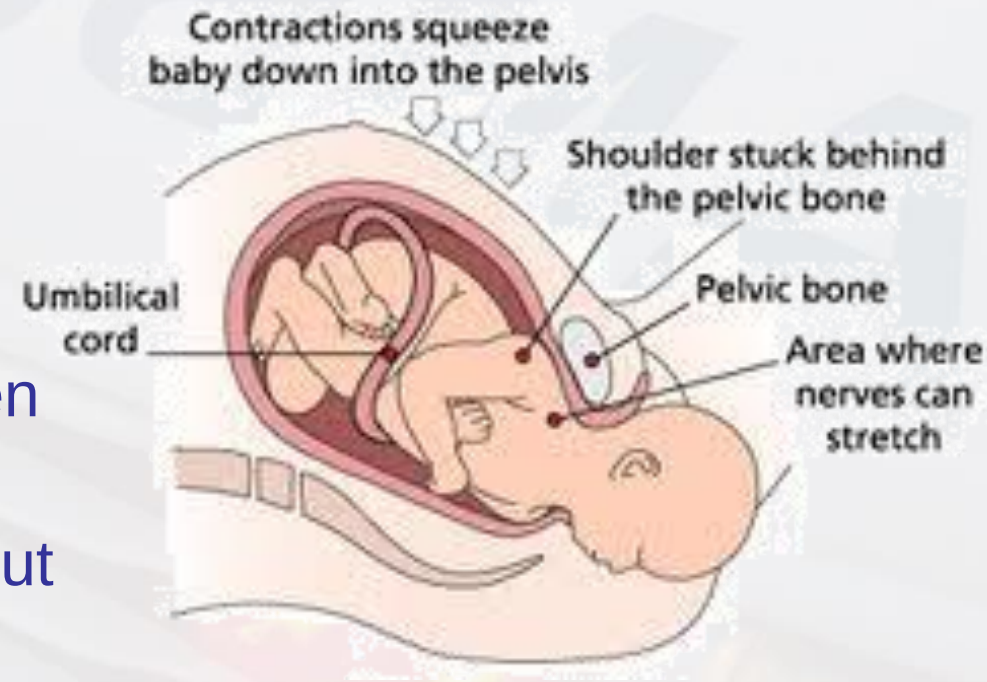

Shoulder Dystocia

- Risk Factors – may or may not be present
  - Prior shoulder dystocia
  - Poorly controlled diabetes
  - Patient obesity (or > 20kg weight gain during pregnancy)
  - Past due date

Shoulder Dystocia

- Associated complications (Fetal)
  - Clavicle or humeral fracture
  - Transient or permanent brachial plexus palsy
  - Hypoxia
  - Asphyxia
  - Death
- Adult/patient
  - Postpartum hemorrhage
  - Vaginal lacerations or laceration into the rectum
  - Cervical tears
  - Uterine rupture

Shoulder Dystocia

- Begin manoeuvers as soon as signs of dystocia are noted
- Inform the patient and communicate clearly
- Follow ALARM acronym
  - A – Ask for help (you will need 2 people)
  - L – lift legs (McRoberts Manoeuvre)
  - A – adduct shoulder (suprapubic pressure)
  - R – Roll Over – (Gaskin's manoeuvre)
  - M – manual delivery of posterior arm

Shoulder Dystocia - McRoberts

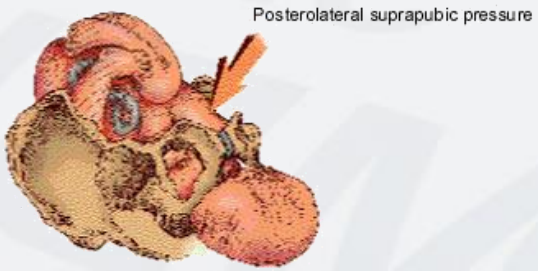

© 2001 Floyd E. Hosmer

- ❖ Lift Mom's legs to knee-chest position
- ❖ Control Mom's breathing

1. Lower the head to birth the anterior shoulder
2. Apply suprapubic pressure down and laterally

Shoulder Dystocia

- If McRoberts manoeuver fails, attempt Gaskin manoeuvre
  - Assist quick position change – guide patient onto hands and knees (make sure you document this)
  - Apply upward lateral flexion to assist with delivery of the body

Figure 3. The Gaskin maneuver. Placing the mother in the all-fours position may allow the posterior shoulder to descend. Reprinted with permission from Kovavisarach E. The "all-fours" maneuver for the management of shoulder dystocia. Int J Gynaecol Obstet 2006;95(2):153–4.

Shoulder Dystocia

- Birthing the posterior shoulder
  - If hand is visible, grab wrist and assist with delivery of the arm

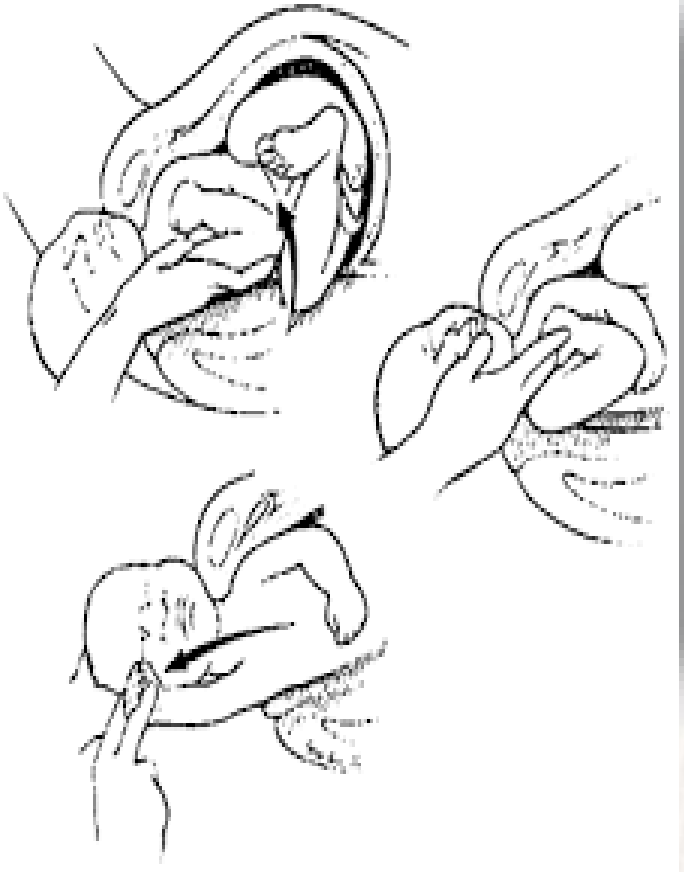

Shoulder Dystocia

- If ALARM manouvres are not successful:
  - Request partner paramedic perform them again
  - If unsuccessful after 2 attempts , transport immediately. (fetal survival rates are low if delivery is not successful)

Prolapsed Cord

- The umbilical cord precedes the fetal presenting part – “prolapsed cord”.
- Elevate the hips, administer oxygen, and keep warm.
- If the umbilical cord is seen in the vagina
  - Check for pulse in the cord
    - If pulse present, make 1 attempt to gently push cord back into canal
    - If no pulse: insert two gloved fingers to raise the fetus off the cord. Do not push cord back.
- Wrap cord in sterile moist towel.
- Transport immediately; do not attempt delivery.

Prolapsed Cord

- Elevate the hips
- IV, fluid prn, O_2 prn
- Keep baby's head away from cord
- Wrap cord in sterile moist towel
- Transport
- Continue pressure on baby's head

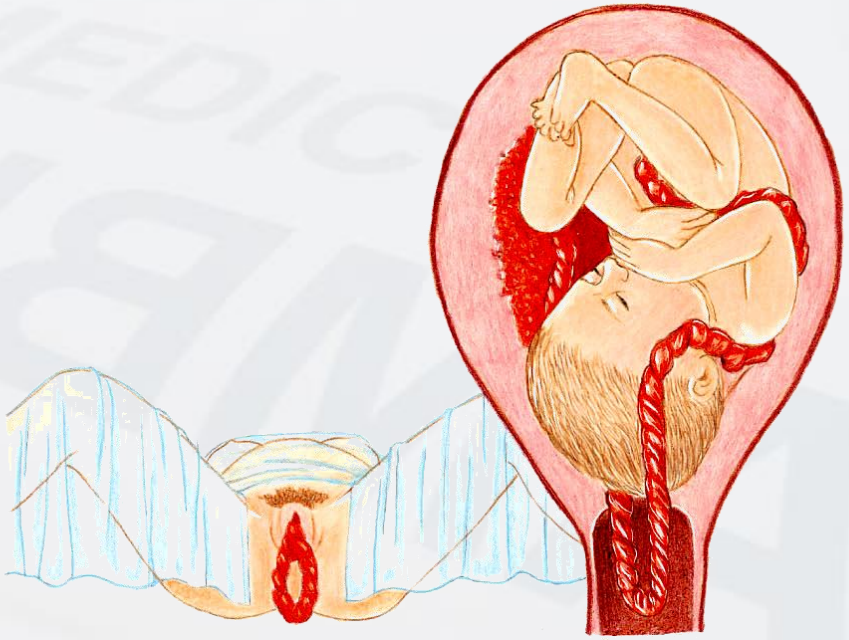

- Elevate hips, administer oxygen, and keep warm.
- Keep baby's head away from cord.
- Do not attempt to push cord back.
- Wrap cord in sterile moist towel.
- Transport mother to hospital, continuing pressure on baby's head.

FIGURE 40-21 Prolapsed cord.

Prolapsed Cord – Alternate positions

- Slow starts-stops and slow turns when driving

Knee-chest position

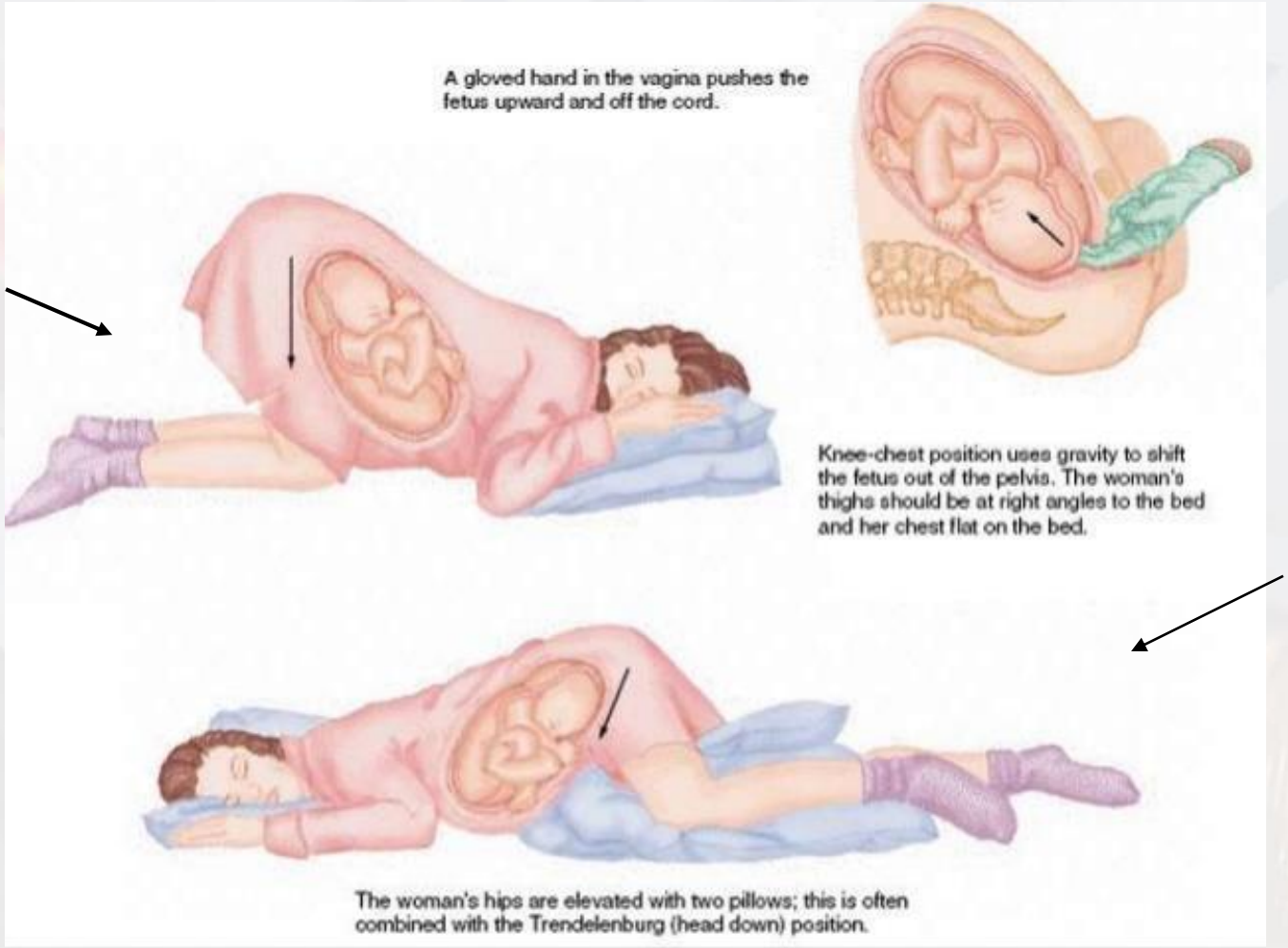

Exaggerated Sims position

Limb Presentation

- Place the mother in hands-knees position
- IV, fluid prn, O_2 prn
- Deliver at scene only if necessary (contact BHP)

or

- Transport immediately

Other Abnormal Presentations

- Reassure the mother
- IV, fluid prn, O_2 prn
- Transport immediately
- If delivery appears inevitable, patch to BHP for consult

Multiple Births

- In twin births, labour starts earlier and babies are smaller.
- Follow normal guidelines, but have additional personnel and equipment.
  - Clamp and cut cord of first baby immediately – it cannot be known if placentas are connected
  - Provide immediate care to first neonate
  - Consider transport before second baby is born – mean intervals between birth of twins is 17- 21 minutes
- Prevent hypothermia.

Cephalopelvic Disproportion

- Infant's head is too big to pass through pelvis easily.
  - Causes include oversized fetus, hydrocephalus, conjoined twins, or fetal tumors.
- If not recognized, can cause uterine rupture.
- Usually requires cesarean section.
- IV, fluid prn, O_2 prn
- Rapid transport .

Precipitous Delivery

- Occurs in less than 3 hours of commencement of regular contractions.
- Usually in patients in grand multipara, fetal trauma, tearing of cord, or maternal lacerations.
- Occurs in 0.1-3% of all labour and births (as cited in PESP, 2017)
- Associated risk of perineal lacerations and PPH

Note:

Multipara = given birth 2 or more times

Grand Multipara = given birth 5 or more times

Precipitous delivery

- Be ready for rapid delivery , and attempt to control the head.
- Encourage patient to breathe/pant – not push during contractions
- Use one hand to guard the perineum and apply gently counter-pressure to vertex when crowning
- Provide care as per normal delivery

Post-partum Hemorrhage

- Defined as a loss of more than 500 cc of blood following delivery.
- Estimated to occur in 2-6% of all births (as cited in PESP, 2017)
- Presenting symptoms
  - ***Uterine atony*** – soft and not/poorly contracted
  - Placenta not delivered within 30 min of birth
  - ***Incomplete placenta***
  - Severe abdominal pain
  - Unable to palpate fundus

Postpartum Hemorrhage -Management

- If placenta UNDELIVERED and patient STABLE
  - Transport – Load and GO
  - SpO_2
  - Oxytocin
  - IV, fluid/bolus prn,
  - O_2 prn
  - ECG, monitor vitals
  - Assess fundus for uterine atony

Postpartum Hemorrhage -Management

- If placenta is ***UNDELIVERED*** and ***UNSTABLE***
  - Attempt to deliver the placenta (CCT)
  - If unable to deliver placenta – perform ***external bimanual compression –*** apply pressure for as long as possible
  - Avoid fundal/uterine massage (this will minimize bleeding when placenta is delivered

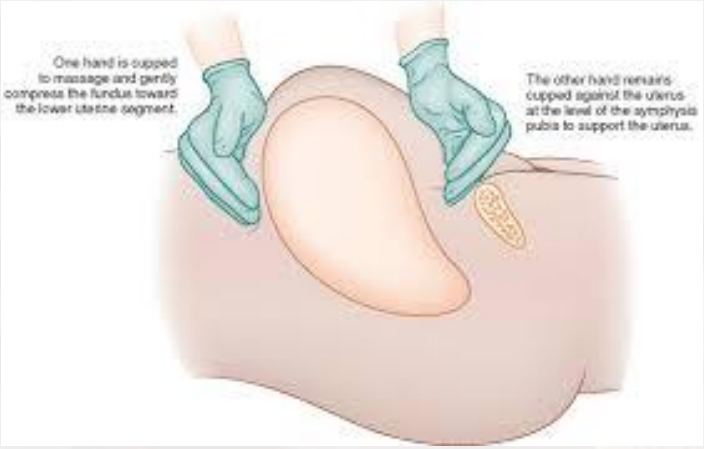

Postpartum Hemorrhage - Management

- If the placenta has ***DELIVERED*** and patient is ***UNSTABLE***
  - Perform external uterine massage (to stimulate contractions)
  - Place a hand on the patients lower abdomen and use firm, smooth, circular movements
  - If bleeding continues, perform external bimanual compression

Postpartum Hemorrhage -Management

- If bleeding suspected form lower genital trauma
  - Inspect area and apply compression with sterile gauze
  - Rapid transport

Uterine Rupture

- Tearing, or rupture, of the uterus
- Severe abdominal pain
- Abdomen is often tender and rigid
- Fetal heart tones are absent
- Treat for shock
- IV, fluid prn, O_2 prn
- Transport patient rapidly – surgical intervention required

Uterine Inversion

- Uterus turns inside out after delivery and extends through the cervix
- Blood loss ranges from 800 to 1,800 cc
- Begin fluid resuscitation
- Make one attempt to replace the uterus.
- If this fails, cover the uterus with towels moistened with saline
- IV, fluid prn, O_2 prn
- Transport immediately

Pulmonary Embolism

- Venous thromboembolism
  - Likely due to venous stasis and changes in blood coagulation during pregnancy
  - 1 case in 200-1400 deliveries
- Presents with sudden severe dyspnea and sharp chest pain
  - O_2, PPV prn
  - Monitor patient closely
  - Transport immediately

Amniotic Fluid Embolism

- rare obstetric emergency
  - 1 case per 8,000-30,000 pregnancies **(eMedicine: http://www.emedicine.com/med/topic122.htm)**
- amniotic fluid, fetal cells, hair, or other debris enter the maternal circulation
- Can lead to DIC

Amniotic Fluid Embolism

- Signs & Symptoms
  - Hypotension
  - Dyspnea
  - Seizure
  - Cough
  - Cyanosis
  - Fetal bradycardia: In response to the hypoxic insult
  - Pulmonary edema
  - Cardiac arrest
- Transport
- Supportive care

QUESTIONS